



## Very late stent thrombosis of bare-metal coronary stent nine years after primary percutaneous coronary intervention

Veoma kasna tromboza metalnog stenta devet godina nakon primarne perkutane koronarne intervencije

Predrag Djurić<sup>\*†</sup>, Slobodan Obradović<sup>†‡</sup>, Zoran Stajić<sup>\*</sup>, Marijan Spasić<sup>‡</sup>,  
Radomir Matunović<sup>\*†</sup>, Radoslav Romanović<sup>†‡</sup>, Nemanja Djenić<sup>†‡</sup>, Zoran Jović<sup>\*†</sup>

<sup>\*</sup>Clinic of Cardiology, <sup>‡</sup>Clinic of Urgent Internal Medicine, Military Medical Academy, Belgrade, Serbia; <sup>†</sup>Faculty of Medicine of the Military Medical Academy, University of Defence, Belgrade, Serbia

### Abstract

**Introduction.** Stent thrombosis (ST) in clinical practice can be classified according to time of onset as early (0–30 days after stent implantation), which is further divided into acute (< 24 hours) and subacute (1–30 days), late (> 30 days) and very late (> 12 months). Myocardial reinfarction due to very late ST in a patient receiving antithrombotic therapy is very rare, and potentially fatal. The procedure alone and related mechanical factors seem to be associated with acute/subacute ST. On the other hand, in-stent neoatherosclerosis, inflammation, premature cessation of antiplatelet therapy, as well as stent fracture, stent malapposition, uncovered stent struts may play role in late/very late ST. Some findings implicate that the etiology of very late ST of bare-metal stent (BMS) is quite different from those following drug-eluting stent (DES) implantation. **Case report.** We presented a 56-year old male with acute inferoposterior ST segment elevation myocardial infarction (STEMI) related to very late stent thrombosis, 9 years after BMS implantation, despite antithrombotic therapy. Thrombus aspiration was successfully performed followed by percutaneous coronary intervention (PCI) with implantation of DES into the previously implanted two stents to solve the in-stent restenosis. **Conclusion.** Very late stent thrombosis, although fortunately very rare, not completely understood, might cause myocardial reinfarction, but could be successfully treated with thrombus aspiration followed by primary PCI. Very late ST in the presented patient might be connected with neointimal plaque rupture, followed by thrombotic events.

### Key words:

stents; drug-eluting stents; thrombosis; myocardial infarction; angioplasty, balloon.

### Apstrakt

**Uvod.** Tromboza stenta (ST) može se klasifikovati u kliničkoj praksi, prema vremenu nastanka, u ranu (0–30 dana nakon implantacije stenta), koju možemo dalje podeliti na akutnu, ukoliko se javi u prva 24 h, subakutnu (1–30 dana), kasnu (> 30 dana) i veoma kasnu (> 12 meseci). Reinfarkt miokarda usled veoma kasne ST kod bolesnika na antiagregacionoj terapiji javlja se veoma retko i može biti smrtonosan. Proceduralni i tehnički faktori su povezani sa akutnom/subakutnom trombozom stenta. S druge strane, neoateroskleroza u području stenta, upala, prerano prekidanje antiagregacione terapije, kao i neadekvatna pozicija stenta igraju važnu ulogu u kasnoj/veoma kasnoj ST. Neka istraživanja pokazala su da je etiologija veoma kasne tromboze metalnog stenta (BMS) u značajnoj meri drugačija od one nakon implantacije stenta obloženog lekom (DES). **Prikaz bolesnika.** Prikazali smo 56-godišnjeg muškarca sa akutnim inferoposteriornim infarktom miokarda sa elevacijom ST segmenta (STEMI) usled veoma kasne tromboze stenta, 9 godina nakon implantacije BMS, uprkos primeni antiagregacione terapije. Učinjena je uspešna tromboaspiracija, nakon čega je urađena primarna perkutana koronarna intervencija (PKI) sa ugradnjom jednog DES na mestu prethodno implantiranih stentova i tako lečili *in-stent* restenozu. **Zaključak.** Veoma kasna tromboza stenta, iako srećom retka i još nedovoljno razjašnjena, može izazvati reinfarkt miokarda, ali se može uspešno lečiti tromboaspiracijom i primarnom PKI. Ruptura plaka neointime sa posledičnom trombozom može biti uzrok veoma kasne tromboze stenta kod prikazanog bolesnika.

### Ključne reči:

stentovi; stentovi, lekom obloženi; tromboza; infarkt miokarda; angioplastika, balonska.

## Introduction

Stent thrombosis (ST) in clinical practice, can be classified according to the time of onset, as: early (0–30 days after stent implantation), further divided into acute (< 24 hours) and subacute (1–30 days); late (> 30 days); and very late (> 12 months).

The procedure alone and related mechanical factors seem to be associated with acute/subacute ST. On the other hand, inflammation, premature cessation of anti-platelet therapy, as well as stent fracture, stent malapposition, uncovered stent struts play role in late/very late ST. Very late ST after stent implantation is more frequent after drug-eluting stent (DES) implantation than after bare-metal stent (BMS) implantation<sup>1</sup>. Moreover, the risk of very late ST after DES seems to be even higher in patients with ST segment elevation myocardial infarction (STEMI) compared with those with stable coronary artery disease<sup>2,3</sup>. Consequently, professional societies have recommended the use of dual antiplatelet therapy (DAT) minimum for 12 months after DES implantation<sup>4</sup>. Actually, very late ST is not common in clinical practice following BMS implantation. Some findings implicate that the etiology of very late ST of BMS is quite different from those following DES implantation.

## Case report

We presented a 56-year-old man with chest pain during one hour before admission, with propagation in the left shoulder, as well as fatigue and weakness. Previously, the patient had the history of dyslipidemia, high blood pressure, family history of coronary artery disease (CAD). Also, the patient was a former smoker. Nine years before he had myocardial infarction of the inferoposterior wall and underwent recanalization of the right coronary artery (RCA). Balloon NC SPRINTER 3.0 × 19 mm, two bare metals stents (BMS): JOMED 3.5 × 12 mm and JOMED 3.0 × 19 mm at 14 atm and balloon angioplasty were used for percutaneous coronary intervention (PCI) on the middle part of RCA. During further follow-up 9 years, the patient did not have any chest pain. He was on dual antithrombotic therapy (clopidogrel 75 mg and aspirin 100 mg *per day*) during the first year, followed by aspirin alone 100 mg *per day*.

Just before admission, electrocardiography (ECG) showed sinus rhythm, heart rate 73 bpm, ST segment eleva-

tion in inferior leads, marked down-ST segment depression with biphasic, dominant negative T waves from V1-V3 (Figure 1a).

In the right precordial leads there were no significant ST-segment changes (Figure 1b), that excluded signs of myocardial infarction of the right ventricular wall.

The patient was the New York Heart Association (NYHA) functional class II and had low blood pressure, 100/70 mmHg. Laboratory analyses revealed creatine kinase (CK) 797 U/L, MB fraction 50 U/L, alanine aminotransferase (ALT) 52 U/L, aspartate aminotransferase (AST) 101 U/L, lactate dehydrogenase (LDH) 386 U/L, total cholesterol 6.93 mmol/L, triglycerides 1.56 mmol/L. Other laboratory parameters were normal.

Transthoracic echocardiography (TTE) revealed normal left ventricular dimension, with hypokinesis of basal and middle segments of inferior and posterior wall with moderate to severe decreased left ventricular ejection fraction (LVEF 45%).

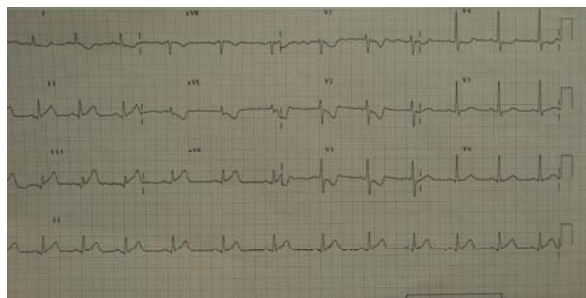
Coronary angiography was immediately performed using the right transfemoral approach and revealed the atherosclerotic left anterior descending artery (LAD), with narrow tubular stenosis diameter of 60–70% in the proximal segment and second stenosis of 80% in the middle part of the LAD. At the distal part of LAD there were 2 stenosis, one between 50% and 60%, and the second 70–80%.

The second diagonal artery had ostial stenosis of 90%. (Medina 1, 0, 1). Proximal circumflex (Cx) artery had stenosis of 40%, and without significant stenosis in the distal part (Figure 2).

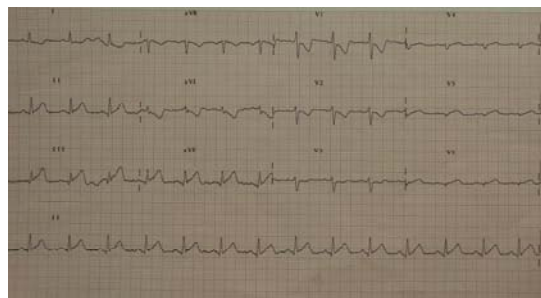
Dominant right coronary artery (RCA) had stenosis of 99% in the middle segment with a huge thrombus into the previously implanted stents (Figures 3).

We decided to perform thrombus aspiration (TA) with the Export Advance Medtronic aspiration catheter as the first step of revascularization strategy. We started the procedure using 6 French JR Concierge guiding catheter for RCA. After that, ASAHI Fielder guide wire passed into the distal part of RCA to posterolateral branch, and we performed thrombus aspiration (Figures 4).

Figure 4b shows the two quite long thrombuses that indirectly implicated very late thrombosis of stents. Subsequently drug-eluting stent Coracto 3.5 × 25 mm was implanted into the middle segment of the RCA up to 14 atmosphere (Figures 5). The angiographic result was optimal, with no residual RCA stenosis.

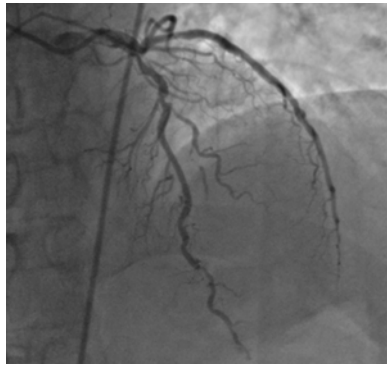


a)

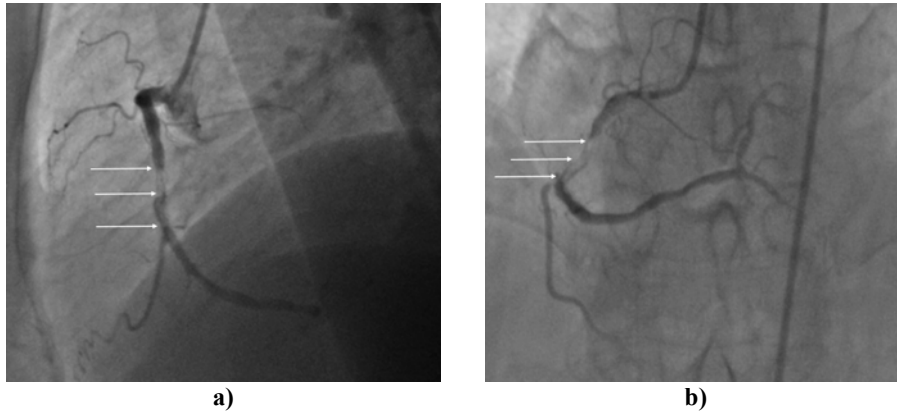


b)

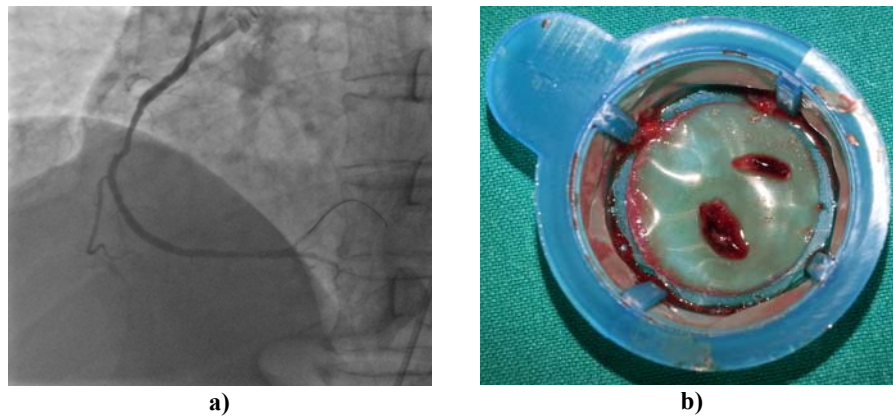
**Fig. 1 – a) Electrocardiography on admission, and b) Electrocardiography of the right precordial leads.**



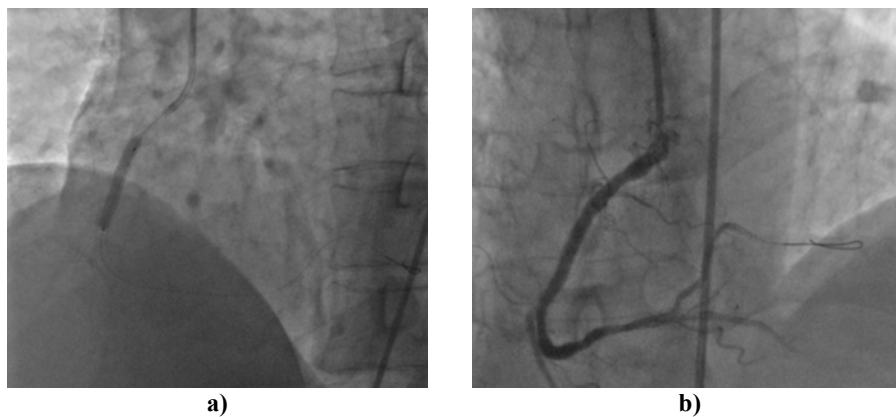
**Fig. 2 – Coronary angiography of the left coronary artery.**



**Fig. 3 – a) Right coronary artery (RCA) with a thrombus (lateral view) and b) Right coronary artery (RCA) with a thrombus (cranial view).**



**Fig. 4 – a) Right coronary artery angiography after aspiration, and b) Two large thrombuses in the right coronary artery.**



**Fig. 5 – a) Implantation of drug-eluting stent (Coracto 3.5 × 25 mm), and b) Final results after stent implantation.**

## Discussion

Stent thrombosis is a catastrophic, a potentially fatal complication of stent implantation which can cause acute myocardial infarction (MI)<sup>5</sup>, cardiogenic shock, life threatening arrhythmias and sudden cardiac death.

BMS, as well as DES, could increase and modify platelet adhesion inducing further thrombotic, inflammatory and vasoconstrictor pathophysiological reactions. Therefore, effective and longer dual anti-platelet therapy is mandatory. Late and very late ST can occur due to malapposition of stent struts, strut fractures, as well as premature cessation of anti-platelet therapy<sup>6,7</sup>. In the following years stents will be covered with endothelial cells (neointimalization) and the need for platelet inhibition decreases due to low risk for thrombus formation inside BMS.

We presented a successful unusual results in a 56-year-old male patient with acute inferoposterior STEMI due to very late stent thrombosis (ST) despite antithrombotic therapy (aspirin + clopidogrel for one year followed by aspirin alone). The patient had myocardial infarction of the inferoposterior wall 9 years before, with PCI performed on the RCA with two BMS and balloon angioplasty of the LAD. After TA, we implanted one drug-eluting stent into the position of the previously implanted two stents to solve the in-stent restenosis.

Very late ST of BMS is quite rare, but more frequent after DES implantation due to absent endothelialization of the stent struts and delayed arterial healing<sup>8</sup>. DES polymer can provoke hypersensitivity and inflammatory reaction, as well as thrombus formation inside stents and new plaque rupture<sup>8</sup>.

Neointimalization, the occurrence of atheromatous changes within neointimal tissue, is uncommon in early years after BMS implantation. It is considered to occur more frequently five years after placing BMS<sup>9</sup>. Recently conducted retrospective study reported that the cumulative incidence of ST after BMS implantation was 0.5% at 30 days, 0.8% at 1 year, 1.3% at 5 years, and 2.0% at 10 years<sup>10</sup>.

The reason for very late ST in the presented patient might be connected with neointimal plaque rupture, followed by thrombotic events. Unfortunately, because of technical reasons, we could not perform intravascular optical coherence tomography (OCT) or ultrasound (IVUS) imaging which is known enable to a precise analysis of the previously stented lesion.

The results of a meta-analysis with data on 117 762 patients showed that DES are highly efficacious at reducing both the short-term risk and the long-term risk of target vessel revascularization (TVR) or target lesion revascularization (TLR), as well as stent thrombosis, compared with BMS<sup>11</sup>. That was the reason to implant one drug-eluting stent into the

previously implanted two stents. Even more, the same meta-analysis<sup>16</sup> showed a significant reduction in both short and long-term risk of stent thrombosis with the newest DES (everolimus-eluting stents- EES) compared with BMS. Additionally, there were significant differences among DES types both in efficacy and safety. Evidence suggests that EES, sirolimus-eluting stents (SES), and zotarolimus-eluting stents (ZES-R), are the best regarding long-term safety and efficacy among the studied stent types<sup>11</sup>.

Percutaneous coronary intervention, as a revascularization strategy with thrombus aspiration, as an adjunctive therapy, is class IIa recommendation for prevention and treatment of no-reflow according to the Guidelines of European Society of Cardiology<sup>12</sup>.

In patients with ST, emergent PCI is required in order to establish normal coronary perfusion, and in two thirds of patients the procedure is successful<sup>13</sup>. ST has 30-day mortality rates of 10–25%<sup>13</sup>, and every fifth patient with a first stent thrombosis experience a recurrent ST episode within 2 years<sup>13</sup>. Long-term follow-up of randomized DES *versus* BMS studies has reported that the incidence of ST is not likely to be increased after implantation of DES compared to BMS<sup>14</sup>. The total incidence of myocardial infarction and death were similar with BMS and DES<sup>15</sup>. Dual antiplatelet therapy (DAPT) (aspirin plus ticagrelor or prasugrel) are currently recommended for the treatment of patients after PCI with either BMS or DES.

In acute coronary syndrome (ACS) patients, the incidence of ST has been reduced by replacing clopidogrel with recent and more efficient antiplatelet agents (prasugrel and ticagrelor), even though this benefit is achieved at the cost of increased bleeding according to the most recent guidelines and randomized trials<sup>12,16,17</sup>.

Taking into account all the relevant facts due to this case, we decided to continue DAPT with ticagrelor 90 mg twice daily in addition to aspirin 100 mg daily and the patient remained free of symptoms or major adverse cardiac event (MACE) at 6 month follow up.

## Conclusion

This is a very rare case of acute inferoposterior STEMI related to quite late stent thrombosis, 9 years after BMS implantation, despite antithrombotic therapy. We successfully performed thrombus aspiration, followed by PCI with implantation of one drug-eluting stent into the previously implanted two stents to solve the in-stent restenosis. Very late stent thrombosis, although fortunately very rare, not completely understood so far, may cause myocardial reinfarction, but can be successfully treated with thrombus aspiration followed by primary PCI with DES.

## REFERENCES

1. *Kastrati A, Mehilli J, Pache J, Kaiser C, Valgimigli M, Kelbæk H, et al.* Analysis of 14 Trials Comparing Sirolimus-Eluting Stents with Bare-Metal Stents. *N Engl J Med* 2007; 356(10): 1030–9.
2. *Daemen J, Wenaweser P, Tsuchida K, Abrecht L, Vaina S, Morger C, et al.* Early and late coronary stent thrombosis of sirolimus-eluting and paclitaxel-eluting stents in routine clinical practice: data from a large two-institutional cohort study. *Lancet* 2007; 369(9562): 667–78.
3. *Kukreja N, Onuma Y, Garcia-Garcia HM, Daemen J, van Domburg R, Serruys PW.* The Risk of Stent Thrombosis in Patients With

- Acute Coronary Syndromes Treated With Bare-Metal and Drug-Eluting Stents. *JACC Cardiovasc Interv* 2009; 2(6): 534–41.
4. King SB, Smith SC, Hirshfeld JW, Jacobs AK, Morrison DA, Williams DO, et al. 2007 focused update of the ACC/AHA/SCAI 2005 guideline update for percutaneous coronary intervention: a report of the American College of Cardiology/American Heart Association Task Force on Practice Guidelines. *J Am Coll Cardiol* 2008; 51(2): 172–209.
  5. Lagerqvist B, James SK, Stenestrand U, Lindbäck J, Nilsson T, Wallentin L. Long-Term Outcomes with Drug-Eluting Stents versus Bare-Metal Stents in Sweden. *N Engl J Med* 2007; 356(10): 1009–19.
  6. Parodi G, Marcucci R, Valenti R, Gori AM, Migliorini A, Giusti B, et al. High residual platelet reactivity after clopidogrel loading and long-term cardiovascular events among patients with acute coronary syndromes undergoing PCI. *JAMA* 2011; 306(11): 1215–23.
  7. Luscher TF, Steffel J, Eberli FR, Joner M, Nakazawa G, Tanner FC, et al. Drug-Eluting Stent and Coronary Thrombosis: Biological Mechanisms and Clinical Implications. *Circulation* 2007; 115(8): 1051–8.
  8. Joner M, Finn AV, Farb A, Mont EK, Kolodgie FD, Ladich E, et al. Pathology of drug-eluting stents in humans: delayed healing and late thrombotic risk. *J Am Coll Cardiol* 2006; 48(1): 193–202.
  9. Nakazawa G, Otsuka F, Nakano M, Vorpahl M, Yazdani SK, Ladich E, et al. The pathology of neoatherosclerosis in human coronary implants bare-metal and drug-eluting stents. *J Am Coll Cardiol* 2011; 57(11): 1314–22.
  10. Doyle B, Ribal CS, O'Sullivan CJ, Lennon RJ, Wiste HJ, Bell M, et al. Outcomes of stent thrombosis and restenosis during extended follow-up of patients treated with bare-metal coronary stents. *Circulation* 2007; 116(21): 2391–8.
  11. Bangalore S, Kumar S, Fusaro M, Amoroso N, Attubato MJ, Feit E, et al. Short- and long-term outcomes with drug-eluting and bare-metal coronary stents: a mixed-treatment comparison analysis of 117 762 patient-years of follow-up from randomized trials. *Circulation* 2012; 125(23): 2873–91.
  12. O'Gara PT, Kushner FG, Ascheim DD, Casey DE Jr, Chung MK, de Lemos JA, et al. American College of Cardiology Foundation/American Heart Association Task Force on Practice Guidelines. 2013 ACCF/AHA guideline for the management of ST-elevation myocardial infarction: a report of the American College of Cardiology Foundation/American Heart Association Task Force on Practice Guidelines. *Circulation* 2013; 127(4): e362–425.
  13. Burzotta F, Parma A, Pristipino C, Manzoli A, Belloni F, Sardella G, et al. Angiographic and clinical outcome of invasively managed patients with thrombosed coronary bare metal or drug-eluting stents: the OPTIMIST study. *Eur Heart J* 2008; 29(24): 3011–21.
  14. Mauri L, Hsieh W, Massaro JM, Ho KK, D'Agostino R, Cutlip DE. Stent thrombosis in randomized clinical trials of drug-eluting stents. *N Engl J Med* 2007; 356(10): 1020–9.
  15. Kirtane AJ, Gupta A, Iyengar S, Moses JW, Leon MB, Applegate R, et al. Safety and efficacy of drug-eluting and bare metal stents: comprehensive meta-analysis of randomized trials and observational studies. *Circulation* 2009; 119(25): 3198–206.
  16. Cannon CP, Harrington RA, James S, Ardissino D, Becker RC, Emanuelsson H, et al. Comparison of ticagrelor with clopidogrel in patients with a planned invasive strategy for acute coronary syndromes (PLATO): a randomised double-blind study. *Lancet* 2010; 375(9711): 283–93.
  17. Montalescot G, Wiwiot SD, Braunwald E, Murphy SA, Gibson C, McCabe CH, et al. Prasugrel compared with clopidogrel in patients undergoing percutaneous coronary intervention for ST-elevation myocardial infarction (TRITON-TIMI 38): double-blind, randomised controlled trial. *Lancet* 2009; 373(9665): 723–31.

Received on December 24, 2014.

Revised on May 18, 2015.

Accepted on May 20, 2015.

Online First March, 2016.